

## Acute aortic syndrome revisited - Spectrum of imaging findings in MDCT

**Poster No.:** C-1746  
**Congress:** ECR 2012  
**Type:** Educational Exhibit  
**Authors:** H. Nunes Correia<sup>1</sup>, P. Marques<sup>2</sup>, M. Seco<sup>2</sup>, P. Donato<sup>2</sup>, F. Caseiro Alves<sup>2</sup>; <sup>1</sup>Viseu/PT, <sup>2</sup>Coimbra/PT  
**Keywords:** Cardiovascular system, CT-Angiography, Diagnostic procedure, Aneurysms, Hemodynamics / Flow dynamics  
**DOI:** 10.1594/ecr2012/C-1746

Any information contained in this pdf file is automatically generated from digital material submitted to EPOS by third parties in the form of scientific presentations. References to any names, marks, products, or services of third parties or hypertext links to third-party sites or information are provided solely as a convenience to you and do not in any way constitute or imply ECR's endorsement, sponsorship or recommendation of the third party, information, product or service. ECR is not responsible for the content of these pages and does not make any representations regarding the content or accuracy of material in this file.

As per copyright regulations, any unauthorised use of the material or parts thereof as well as commercial reproduction or multiple distribution by any traditional or electronically based reproduction/publication method is strictly prohibited.

You agree to defend, indemnify, and hold ECR harmless from and against any and all claims, damages, costs, and expenses, including attorneys' fees, arising from or related to your use of these pages.

Please note: Links to movies, ppt slideshows and any other multimedia files are not available in the pdf version of presentations.

[www.myESR.org](http://www.myESR.org)

# Learning objectives

- To review the spectrum of imaging findings in MD-CT of acute aortic syndromes of non-traumatic disease entities of the aorta namely penetrating atherosclerotic ulcer, intramural hematoma, aortic dissection and complications, and unstable aortic aneurysm.
- To illustrate the key findings related to each disease and highlight potential pitfalls.
- To review the current literature regarding acute aortic syndrome focusing the management options.

## Background

"Acute aortic syndrome" refers to an inhomogeneous group of conditions that share a common set of signs and symptoms, the pivotal of which is aortic pain. This term was proposed in 2001 by Vilacosta [1] and serves well its function, like the terms acute abdomen or acute coronary syndrome, it fits like a glove.

It comprises aortic dissection (AD), intramural hematoma (IMH), penetrating atherosclerotic ulcer (PAU) and unstable aortic aneurysm.

- **AORTIC DISSECTION**

Aortic dissection is characterized by intimal rupture with the formation of a false lumen, usually parallel to the true lumen ([Fig. 1](#) on page 5). Blood flow within the false lumen can have devastating consequences for organ perfusion. The majority of the patients are hypertensive and the triggering mechanism for dissection to occur is the formation of an intimal tear rupture, where the shearing stress generated by flow is maximal. When a false lumen is created propagation occurs in an anterograde or retrograde fashion. As recently outlined in an article by Yoo [2], the term intimal flap is a misnomer, because the thickness of the outer wall of the false lumen is only one third of the flap thus being more prone to rupture; in this way the dissection flap should be more appropriately named intimo-medial flap. It should be also stressed that aortic dissection is usually related to cystic medial degeneration [3], and individuals at particular risk are those with dilating aortic pathology (bicuspid aortic valve, aortic coarctation, and aortic aneurysm) and arterial hypertension. Other predisposing factors are connective tissue diseases of the aorta, direct trauma, cocaine abuse and pregnancy.

Aortic dissection is estimated to occur annually in 3 - 4 per 100 000 patients, with a 5 to 1 predominance in the male gender [4].

Generally aortic dissections are classified according to the location of the entry tear, the extent of the dissection and the presence or absence of complications.

The DeBakey classification ([Fig. 2](#) on page 5) divides aortic dissections based on where the intimo-medial flap is localized and its extent:

I - dissection that originates in the ascending aorta but propagates to the aortic arch and often beyond;

II - dissection confined to the ascending aorta (proximal to the left subclavian artery);

III - dissection that originates in descending aorta and extends distally (distal to the left subclavian artery).

However the most used classification is the one proposed by Stanford ([Fig. 2](#) on page 5), mainly because of its daily applicability and by its therapeutic implications. Thus a dissection is considered of type A when it involves the ascending aorta or the aortic arch and type B dissections are limited to the descending aorta. About 60 % of aortic dissections are type A, and there is overall consensus that they are surgical emergencies, as they are frequently associated with deadly complications such as pericardial tamponade, acute aortic regurgitation and involvement of the coronary arteries. Type B dissections can be approached in a conservative basis and endovascular stent-graft repair is an emerging therapeutic option in patients with complicated type B dissection.

There is another classification system proposed by Svensson et al [5] and later adopted by the European society of cardiology that approaches dissection and other entities included in acute aortic syndrome as a spectrum of pathology and not isolate entities [Fig. 3](#) on page 6.

The entry tear is often located proximal to the intimo-medial flap and is identified in the majority of cases; however the reentry tear is not frequently identified because it typically consists of a minor defect or defects [2].

We should also point out that dissections are considered acute when they are diagnosed within 2 weeks from the clinical presentation scenario.

- **INTRAMURAL HEMATOMA**

Intramural hematoma (IMH) was first described by Krukenberg in 1920 [6] and it was commonly supposed that its origin was due to spontaneous rupture of the vasa vasorum of media layer. More recently it has been suggested that most IMH results from an entry tear similar to AD, with complete thrombosis of the false lumen [2]. This is not a new concept as it was already mentioned by Krukenberg in 1920. Although we may disagree on the role of intimal tears in this entity, it is widely assumed that disease of the media layer is necessary for IMH to occur. From the functional point of view it is also assumed

that IMH is a blood collection within the aortic wall, not freely communicating with the lumen ([Fig. 4](#) on page 6).

IMH comprises about 10% to 30% of acute aortic syndromes [7], and predisposing factors are the advanced age and hypertension.

IMH is not a static entity but a dynamic one, because it may regress (<30%), progress to classic AD (25-45 %), expand or rupture [4]. Thus, for management options it is usually classified using the Stanford classification system and controversy arise in the management options.

The current treatment for type A is early surgery as they are more likely to progress to dissection, contained rupture or aneurysm formation. However as suggested by Lansman et al [7] conservative treatment criteria for observation include the hemodynamic stability, absence of pain, an aortic diameter < 50 mm, hematoma thickness < 10 mm, no ulcer like projection, small pericardial or pericardial effusion and no tamponade and the absence of aortic regurgitation insufficiency. Type B IMH are subject to conservative treatment, except if they are associated with findings associated with a less favorable outcome, such as ulcer-like projections, in these cases endovascular stent grafts should be used.

- **PENETRATING ATHEROSCLEROTIC ULCER**

They were initially described in 1934 by Shennan et al [8], and were defined as a focal atherosclerotic plaque that erodes the internal elastic lamina and extends in a variable depth into the media ([fig.5](#)). They tend to occur more frequently in men with an advanced age and they may be single or multiple, being predominantly situated in the descending aorta.

The incidence of PAU in acute aortic syndromes ranges from 2,3% to 11 % [7], PAU should be differentiated from atheromatous ulcer in which ulceration is confined within the intima, and so these overlie the expected aortic contour and calcified intima, conversely PAU extends outwardly and beyond the calcified intima ([Fig. 5](#) on page 7).

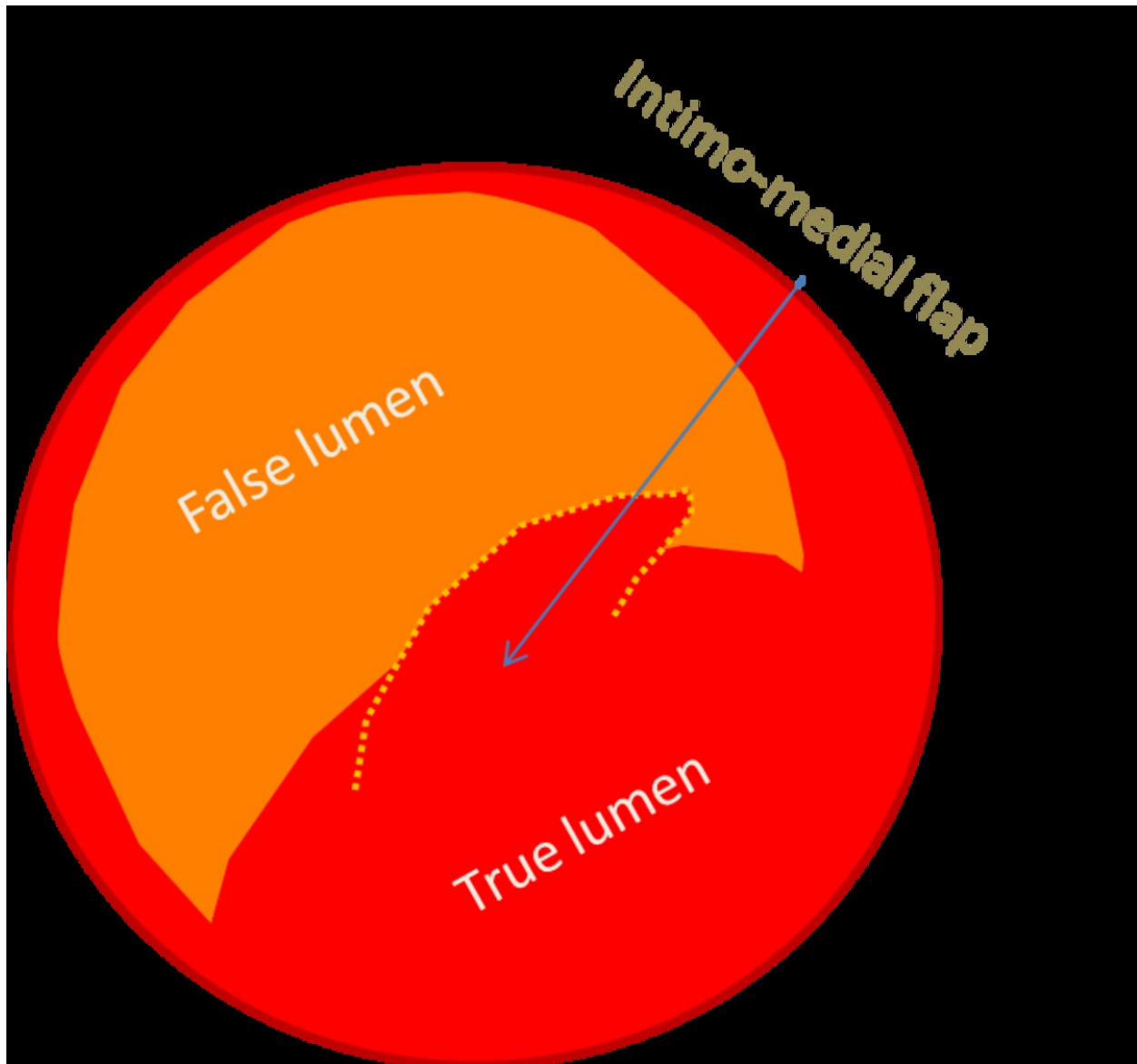
The natural history of PAU is extremely variable, and there is debate about its relationship with its size. Some authors [2, 7] suggest that a depth (>10 mm) and diameter of ulcer (> 20 mm) are independent predictors of lesion progression. However, if asymptomatic, follow-up CT is likely to be more reliable.

As they occur mainly in patients with comorbidities, they should be treated conservatively. Endovascular stent-graft repair has emerged as an attractive method in this group of patients and the criteria for its placement according to Botta et al [9] include pain and rupture in the acute setting; in chronic cases, indications include recurrent pain, aortic diameter > 55 mm, and increase >10 mm/year. It should be stressed that despite the comorbidities and the potential risks in this subgroup of patients, it is now possible to offer them a therapeutic approach.

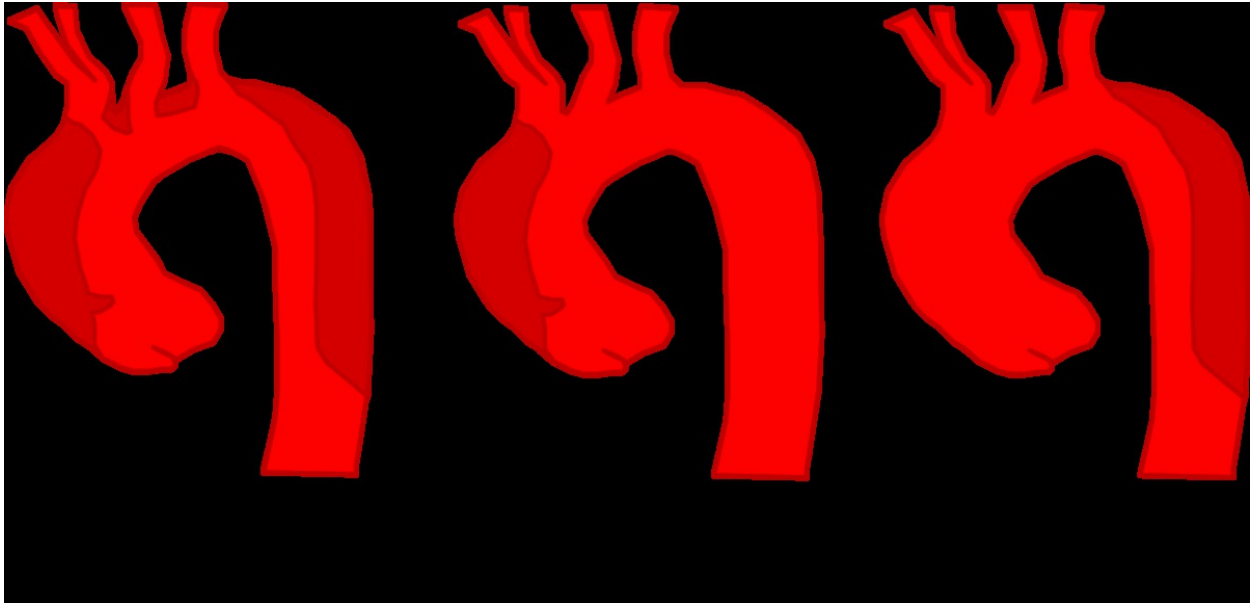
- **UNSTABLE AORTIC ANEURYSM**

The major clinical finding of an aneurysmal rupture is sudden onset pain. Usually the pain precedes major rupture [10] . Various image findings can be used to predict the possibility or risk of an aneurysmal rupture such as size, expansion rate, periaortic hemorrhage, the hyperdense crescent sign, focal discontinuity of the intimal calcifications and the draped aorta sign. From all these findings, the maximal diameter of the aneurysm is the more important factor to for predicting the rupture risk.


**Images for this section:**




**Fig. 1:** Schematic representation of a dissection



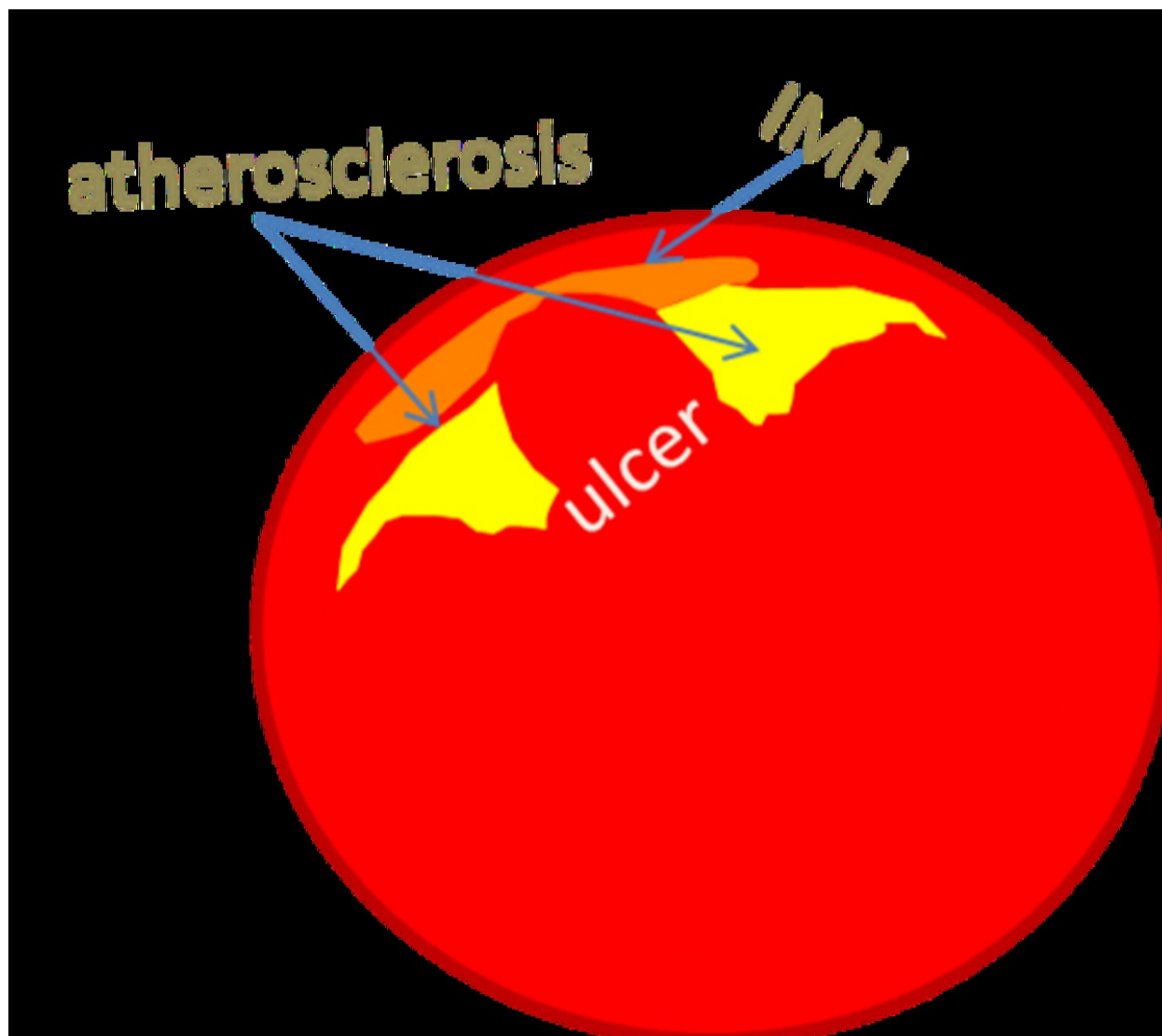
**Fig. 2:** Schematic representation of the DeBakey and Stanford classification systems



**Fig. 3:** Schematic representation of the Svensson classification system: class I-classic double-barrel dissection; class II-intramural hematoma without intimal disruption; class III-intimal tear; class IV-penetrating aortic ulcer; class V-iatrogenic injury



**Fig. 4:** Schematic representation of an intramural hematoma (IMH)



**Fig. 5:** Schematic representation of an penetrating atherosclerotic ulcer (PAU



# Imaging findings OR Procedure details

## AORTIC DISSECTION

Given an examination with a patient presenting with aortic dissection, the following aspects should be referred in the report, as stated by Yoo [2]:

- The extent (Stanford classification)
- Side of entry tear
- Side branch involvement
- Presence of aortic rupture
- Differentiation between the true or false lumen
- The size of false lumen diameter (predictor for aortic rupture)

### CT findings of AD

At non-enhanced CT images it is possible to observe the irregularity of the lumen wall, intramural or periaortic acute thrombus giving the appearance of a high attenuation crescent, widening of the aorta and hyperattenuating collections at the mediastinum, pericardium and pleural space. The displaced intimal calcifications also strongly suggest the diagnosis ([Fig. 6](#) on page 11).

Enhanced CT images show the intimo-medial flap given rise to the true and false lumen, the typical "double-barrel" image ([Fig. 7](#) on page 12). The localization of the entry tear should be referred as is exclusion could be performed by endovascular therapy. Frequently there are aspects that permit to distinguish the true lumen from the false lumen:

1. The cobweb sign refers to faint linear hypodensities that represent incompletely torn connective tissue and is typical of the false lumen ([Fig. 8](#) on page 13).
2. The false lumen has more irregular contour, is usually larger than the true lumen because of the higher pressure and presents acute angles with the intimo-medial flap, the beak sign ([Fig. 9](#) on page 14).
3. The flow in the false lumen is slower, resulting in lesser opacification and has more probability of containing thrombus ([Fig. 10](#) on page 14).
4. The intimo-medial rupture sign
5. The calcifications of the intimal medial layer are located externally to the true lumen ([Fig. 6](#) on page 11).

Intimointimal intussusception is an unusual type of aortic dissection produced by circumferential dissection of the intimal layer. The CT images may show one lumen wrapped around the other lumen, with the inner lumen invariably being the true lumen ([Fig. 11](#) on page 15).

The side branch involvement can be of two types [11]:

- Static obstruction occurs when the intimomedial flap extends directly into the side branch-vessel ([Fig. 12](#) on page 15); the obstruction can be solved by placing a stent into the true lumen of the involved side branch.
- Dynamic obstruction occurs when the intimomedial flap does not extent to the side-branch vessel, however due to high pressure in the false lumen the end organ perfusion is impaired ([Fig. 13](#) on page 16). In these cases the true lumen has a C-Shaped configuration that is concave toward the false lumen, and the obstruction can be treated with a fenestration procedure.

In patients with complicated type B dissection endovascular therapy is an emerging and attractive therapeutic approach in patients that have a sufficient landing zone, characterized by absence of aortic tortuosity more than 5 mm distal to the left subclavian artery ([Fig. 14](#) on page 16).

## **INTRAMURAL HEMATOMA**

It is on unenhanced CT scans that Intramural Hematoma is most conspicuous, appearing as a crescent-shaped area of higher attenuation in the aortic wall ([Fig. 15](#) on page 17, [Fig. 16](#) on page 18). As with typical dissections, intimal calcifications may be displaced internally, into the aortic lumen. On contrast-enhanced CT, the crescent-shaped intramural hematoma remains unenhanced after contrast material administration. As stated before, care should be taken when evaluating the existence of predictors of poor outcome such as the hematoma thickness, aortic diameter and the presence of ulcer like projections ([Fig. 16](#) on page 18).

## **PENETRATING ATHEROSCLEROTIC ULCER**

They usually occur in the descending thoracic aorta or upper abdominal aorta and, quite frequently, they are multiple. Care should be taken in the identification of the dominant or complicated lesion.

These patients present at non-enhanced CT images extensive atherosclerosis, possibly a hyperdense intramural hematoma, displaced intimal calcifications and the ulcer crater is not demonstrated. The presence of an intramural hematoma clearly identifies the ulcer as penetrating ([Fig. 17](#) on page 18).

At enhanced CT images we appreciate a focal ulceration of the aortic wall, usually with acute margins and a contrast collection outside of the expected aortic lumen ([Fig. 18](#) on page 19), there could also be thickening and enhancement of the aortic wall.

When assessing these patients, multiplanar reconstructions are valuable to delineate the ulcer and any mural abnormalities in cases where axial images can be confusing.

As stated before, patients that present with an aortic diameter exceeding 55 mm or have an increase > 10 mm/year are more prone to disease progression and formation of pseudoaneurysms ([Fig. 19](#) on page 19). In these patients endovascular intervention should be considered, and if they present adequate conditions, surgical treatment should

be the adequate management. In patients not suited to treatment, careful CT follow-up is advised, especially during the first month.

## UNSTABLE AORTIC ANEURYSM

When imaging an aneurysm, the maximal diameter is the most important predictor imaging finding for rupture to occur. If the aneurysmal diameter is < 4 cm, the 6 year cumulative incidence of rupture is of about 1 %. Of patients with aneurysms < 5 cm, 25-41 % were expected to experience rupture within five years [10]. Conversely, the aneurysmal length was not found to be associated with the risk of rupture [10].

Due to the aging process, a normal aortic diameter may increase a speed of 0,05 - 0,08 mm/year [12]. Aortic aneurysms may expand exponentially, so larger aneurysms can grow faster. According to Lee et al [10], as a sign of impending rupture, an expansion rate superior to 1 cm / 6 months might be a fair criterion.

The hyperattenuating crescent sign represents an acute hematoma within either the mural thrombus or the aneurysmal wall, being strongly associated with aneurysmal rupture (Fig. 20 on page 20). The specificity of this sign is of 93 % and sensibility of 77%. So even in the absence of rupture, its presence should be referred.

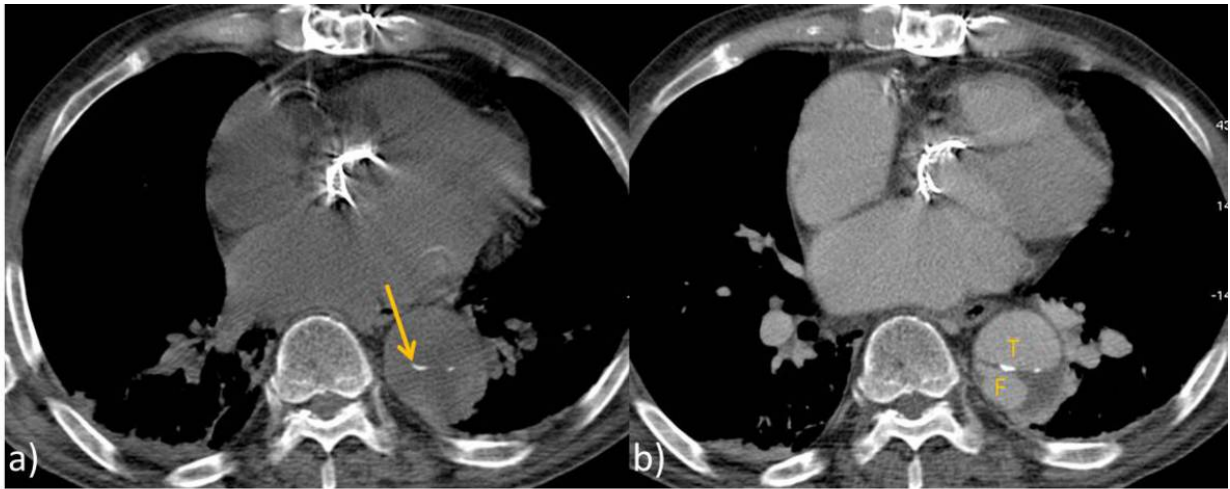
The focal discontinuity of the intimal calcifications, especially if it looks the calcium is pointing away from the expected circumference also should be referred (Fig. 21 on page 21).

The draped aorta sign refers to presence of an unidentifiable posterior aortic wall, and the posterior aorta follows the contour of the spine (Fig. 22 on page 22)

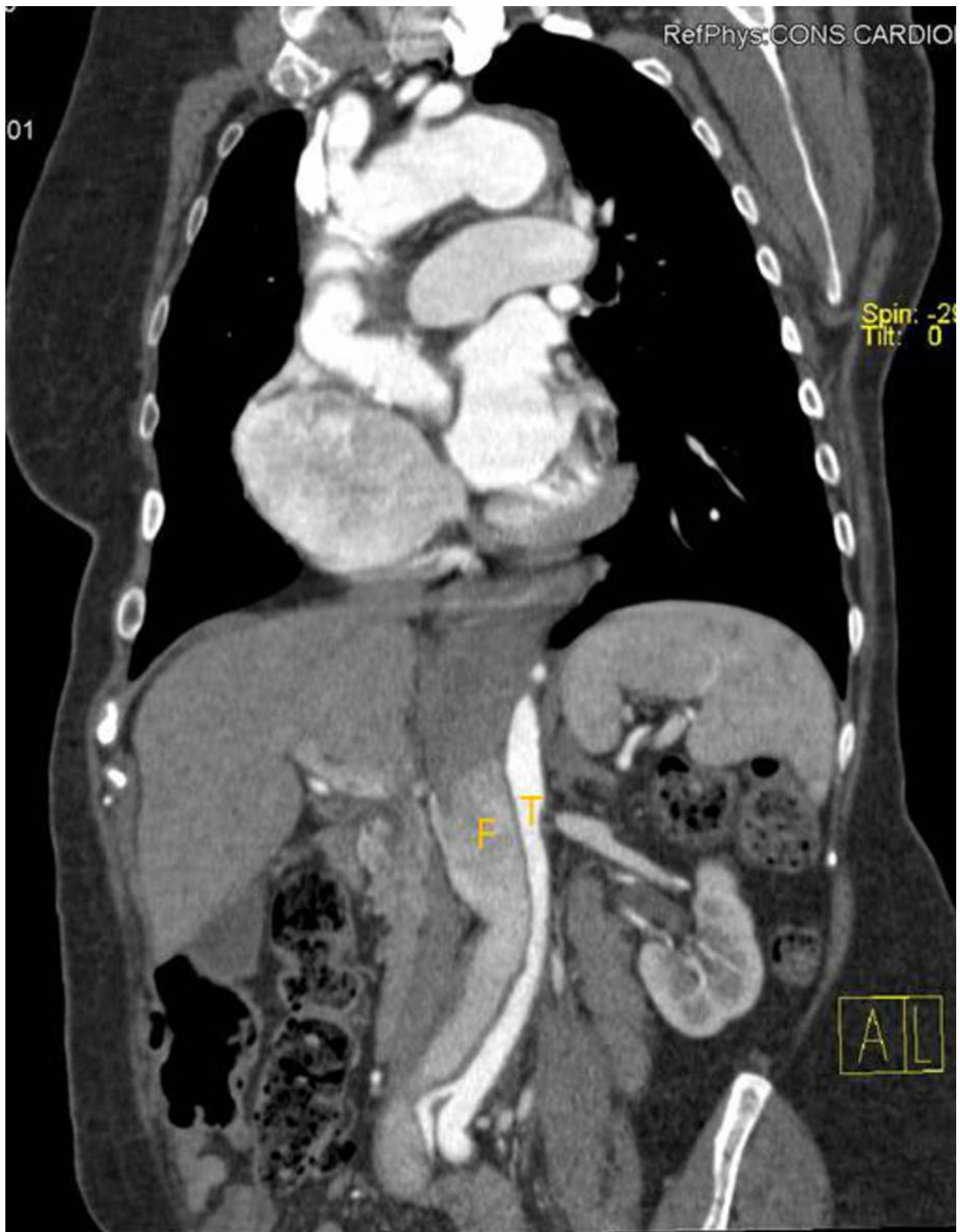
The thoracic aortic rupture is characterized by the presence of hyperattenuating opacities or the presence of mediastinal hematoma. Hemorrhagic pericardial or pleural effusion (Fig. 23 on page 23) can also be observed and hemorrhage from the ascending aorta may enter the perivascular connective tissue of the pulmonary artery and then may extend into the interstium of the lungs.

Abdominal aorta rupture manifests as increased attenuation or stranding of the retroperitoneal fat adjacent to the aorta, obscuring its margin (Fig. 24 on page 24). Acute hemorrhage may not be hyperdense but isodense to the muscle because of lack of clotting or separation between blood cells and serum (Fig. 25 on page 24)

**Images for this section:**

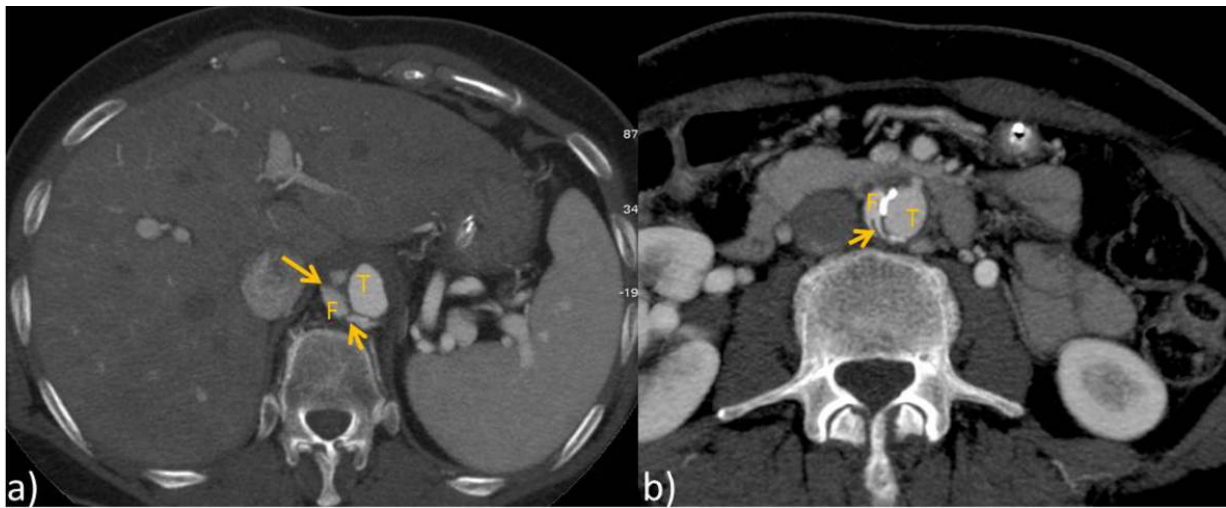


**Fig. 6:** a) Dislocation of the intimal calcification (arrow) at non enhanced axial CT images  
b) At enhanced CT axial images the calcifications are located externally to the true lumen (T)

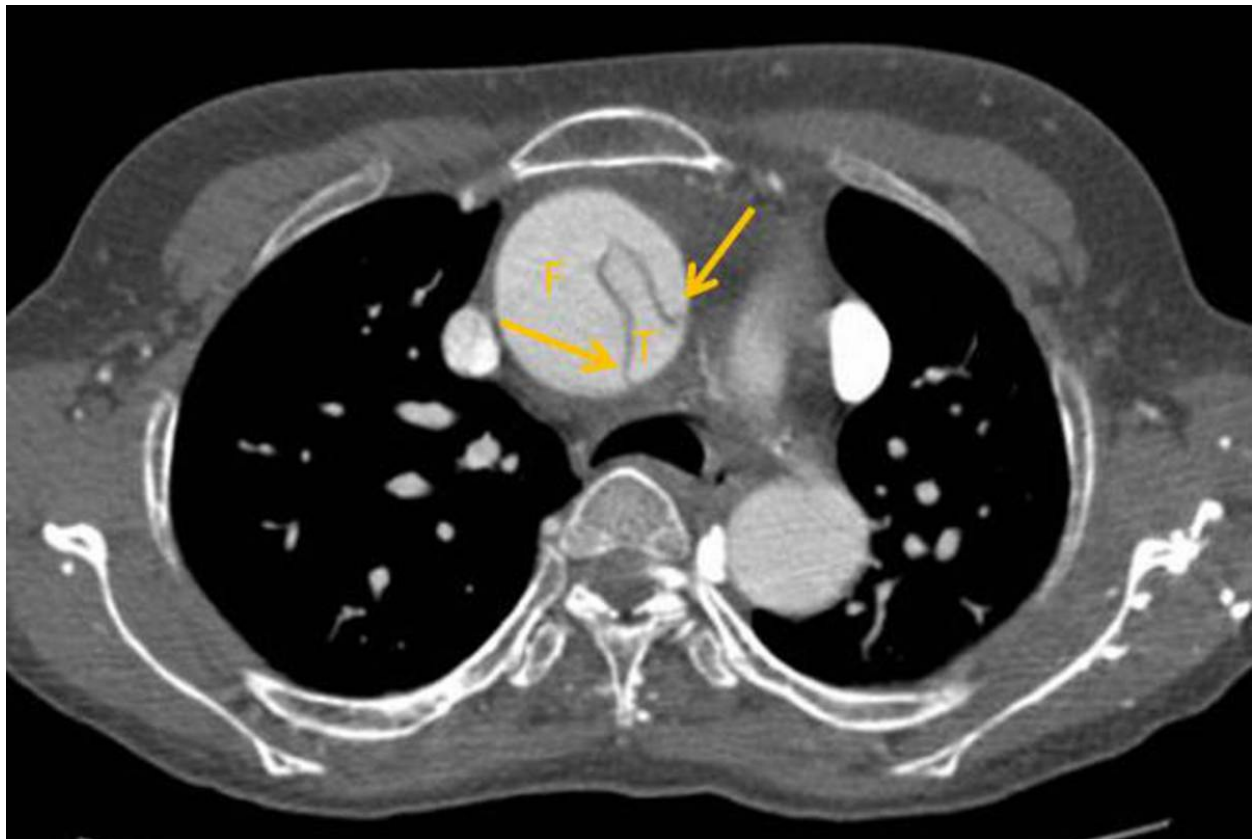


**Fig. 7:** MPR curved image of a patient with type B aortic dissection showing the typical "double barrel image"

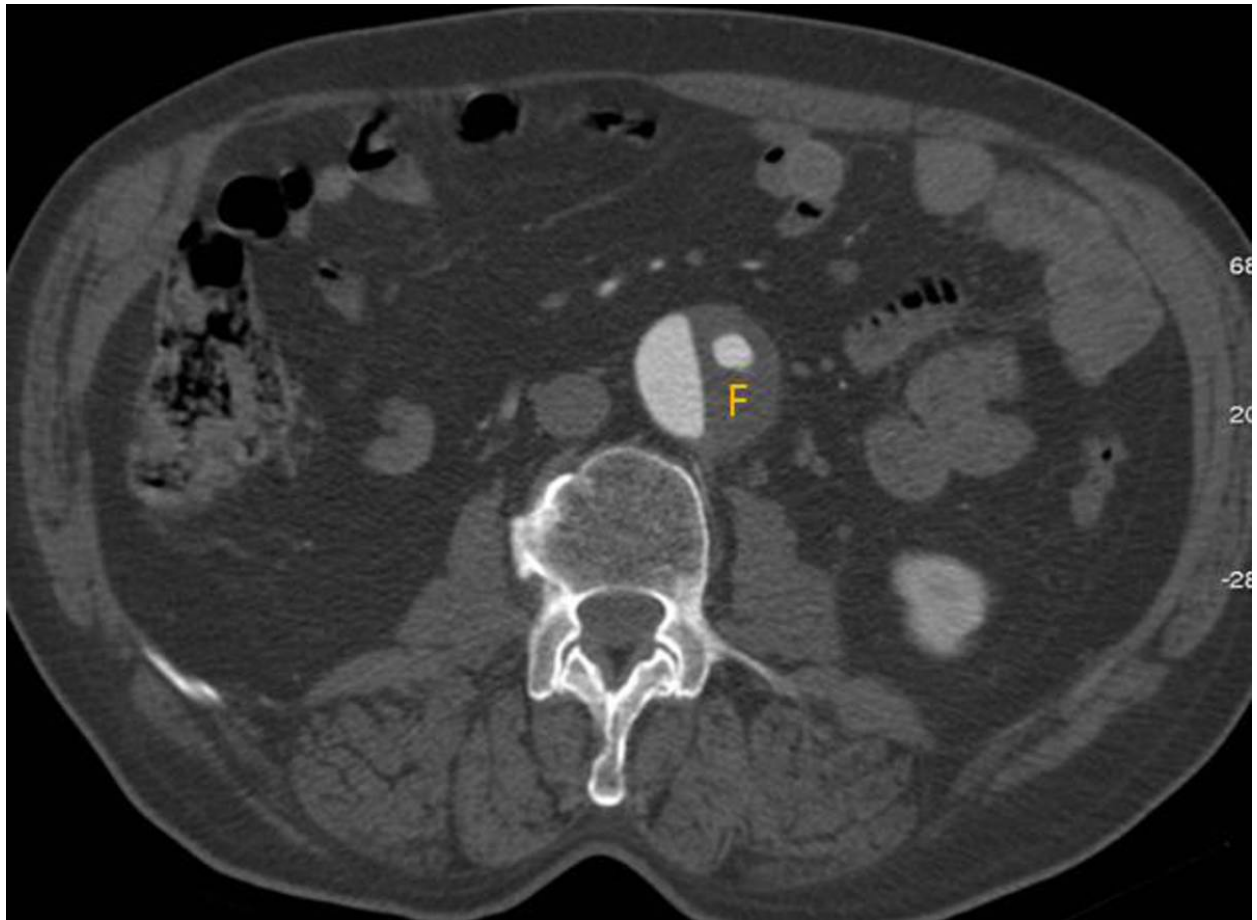



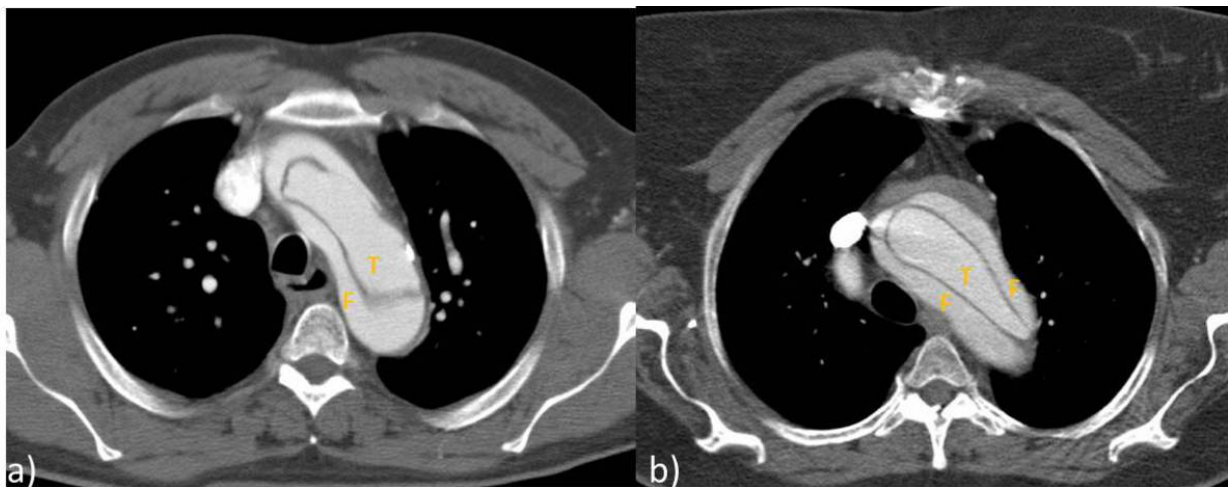
**Fig. 8:** a) b) Enhanced axial CT images from two different patients with type B aortic dissection, demonstrating the cobweb sign. There are faint linear hypodensities (arrow) located in the false lumen (F)



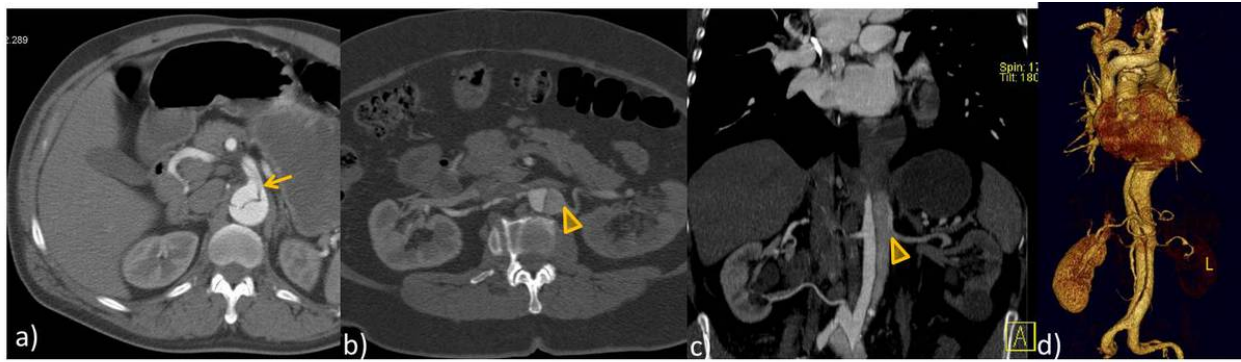
**Fig. 9:** Enhanced axial CT image of a patient with type A aortic dissection showing the "beak" sign (arrow). The false lumen has acute angles with the intimo-medial flap



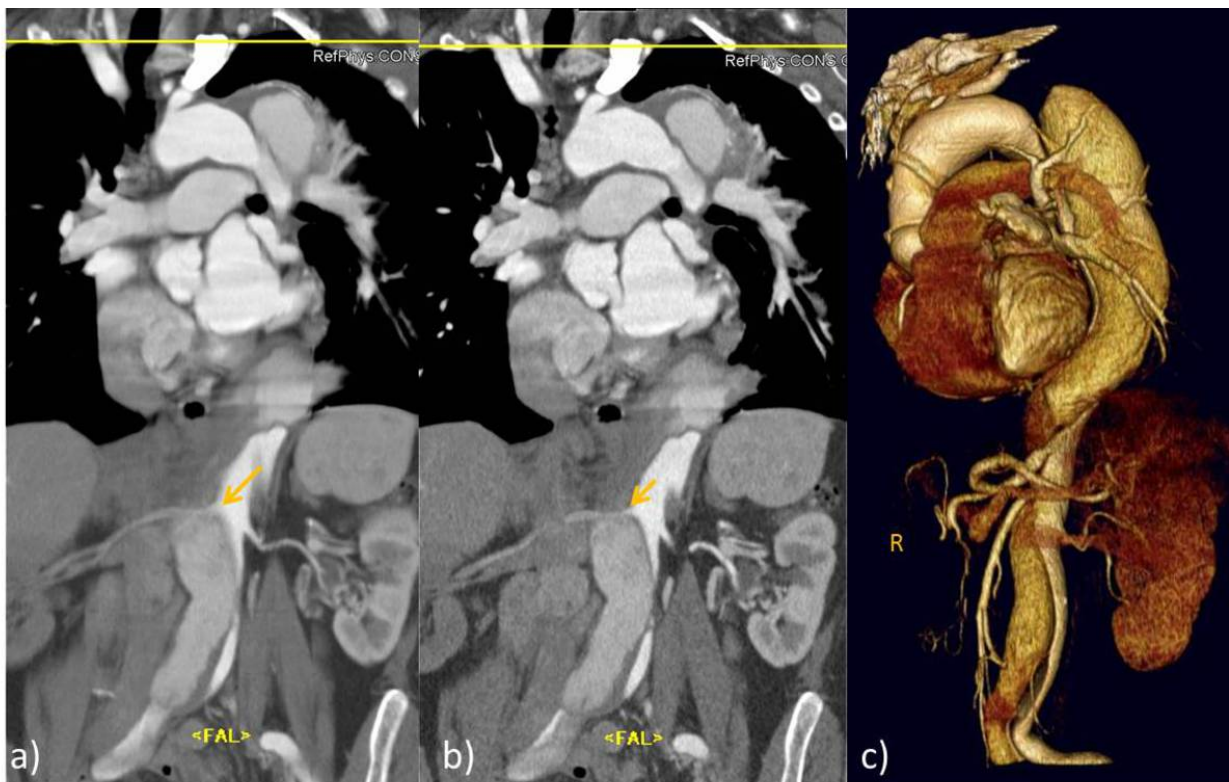
**Fig. 10:** Thrombosis of the false lumen (F)



**Fig. 11:** a) b) Intimo - intimal intussusception - the inner lumen is invariably the true lumen (T), surrounded by the false lumen (F)

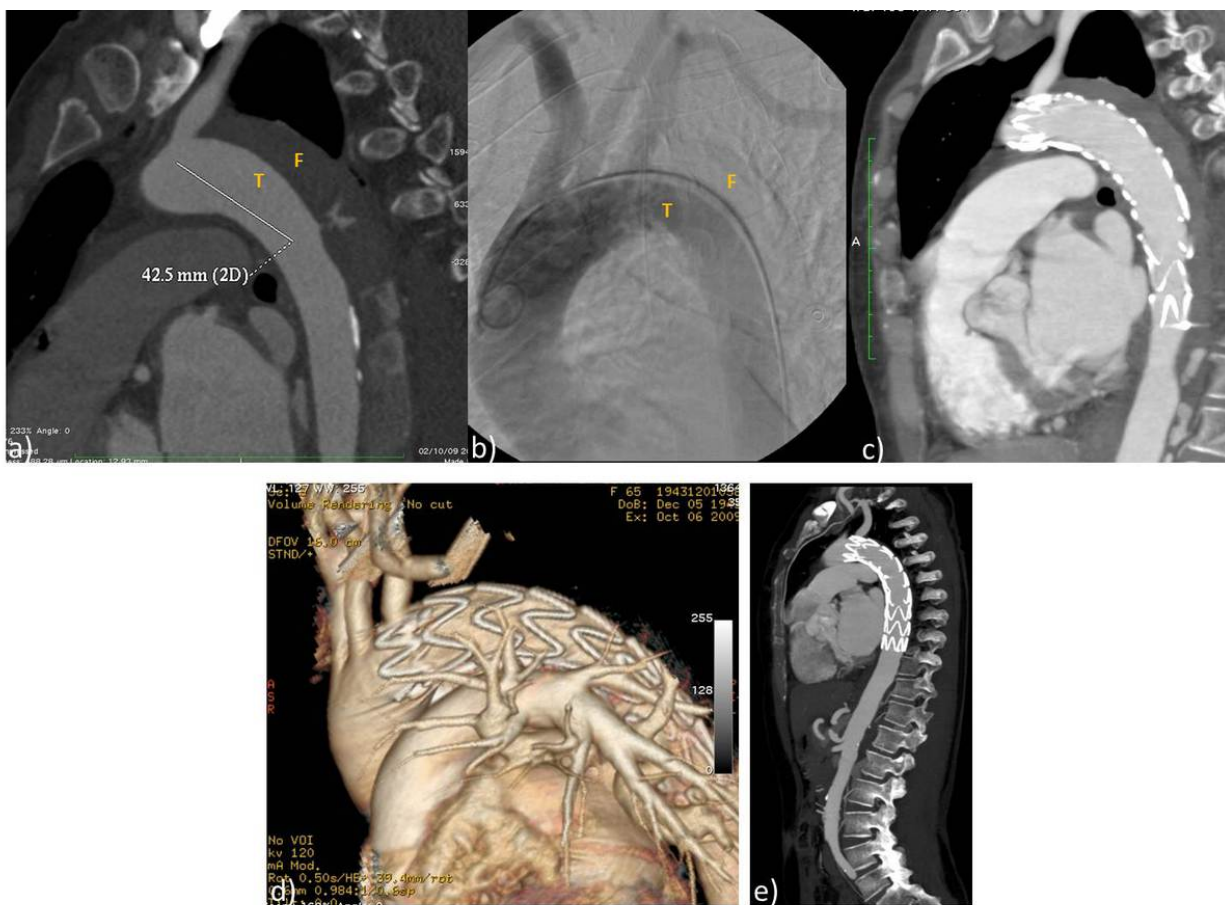


**Fig. 12:** a) Extension of the intimo-medial flap directly to the celiac trunk in a patient with type B aortic dissection (arrow) b) c) curved MPR images showing the origin of the left renal artery in the false lumen in a patient with a type B aortic dissection (arrow head) d) 3d volume rendering image of the same patient in b) and c) demonstrating the perfusion impairment of the left kidney (L)

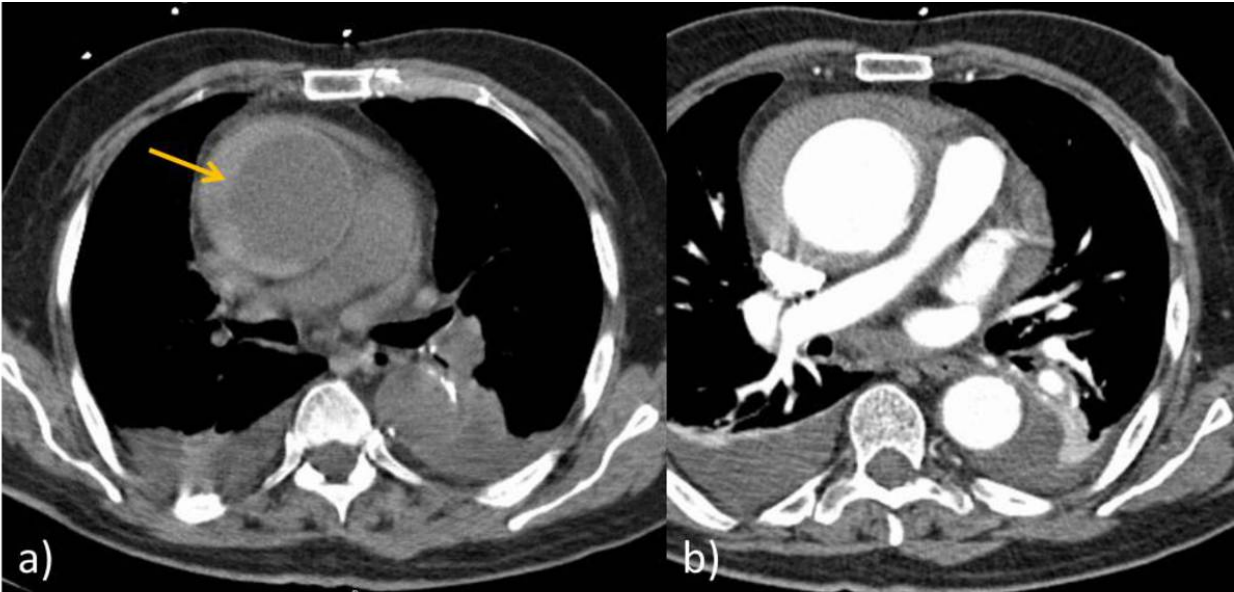


**Fig. 13:** a) b) Curved MPR 5 mm thick image and 1 mm thick images of a patient with a type B aortic dissection, showing the right renal artery arising directly from the true lumen (arrow), however due to high pressure of the false lumen there is right kidney perfusion impairment (R) as demonstrated in the volume rendering image in c)

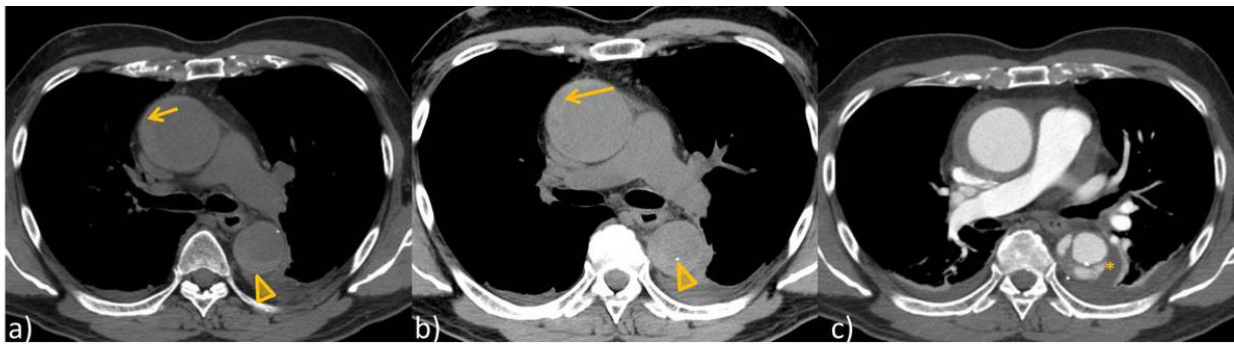




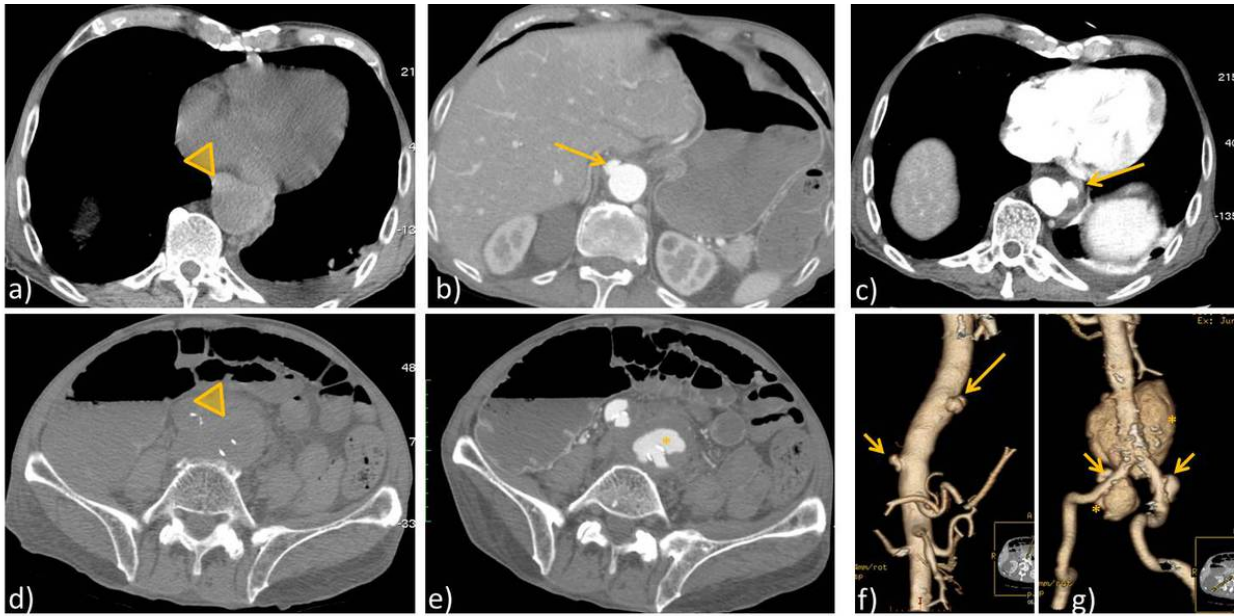
**Fig. 14:** Patient with a type B aortic dissection - a) Sagittal oblique MIP image, showing the true lumen (T) and the false lumen (F) b) angiography of the aortic arch, showing a very faint opacification of the false lumen (F), arising distally to the right subclavian artery c) sagittal oblique MIP image 1 month after stent placement d) volume rendered image of the CT angiography exam performed 1 month after stent placement e) sagittal MIP image of a CT angiography performed 1 year after stent placement demonstrating successful exclusion of the false lumen.



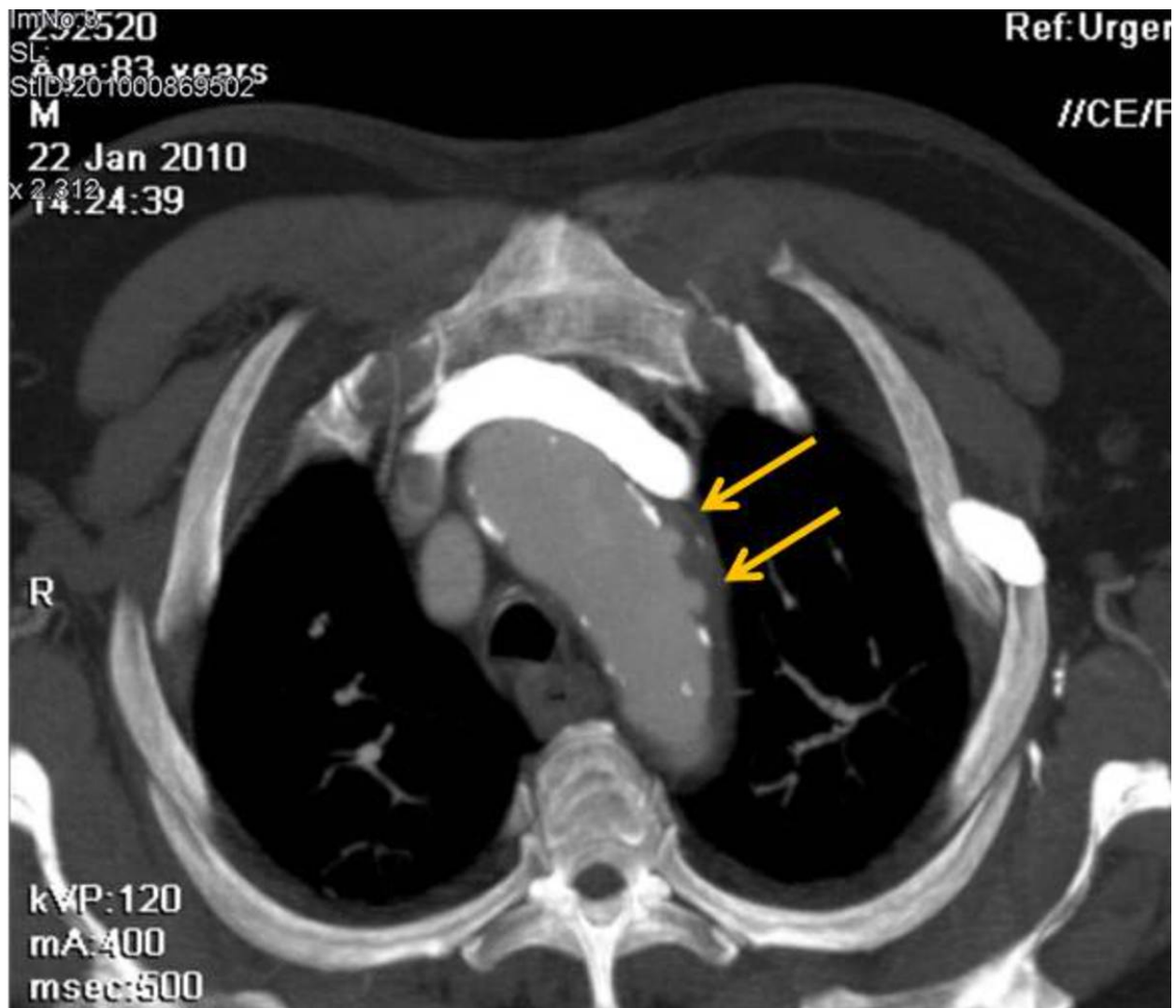
**Fig. 15:** Patient with a type A intramural hematoma - a) Non enhanced axial CT image demonstrating a crescent-shaped area of higher attenuation (arrow) b) At enhanced axial CT images the intramural hematoma it is not evident



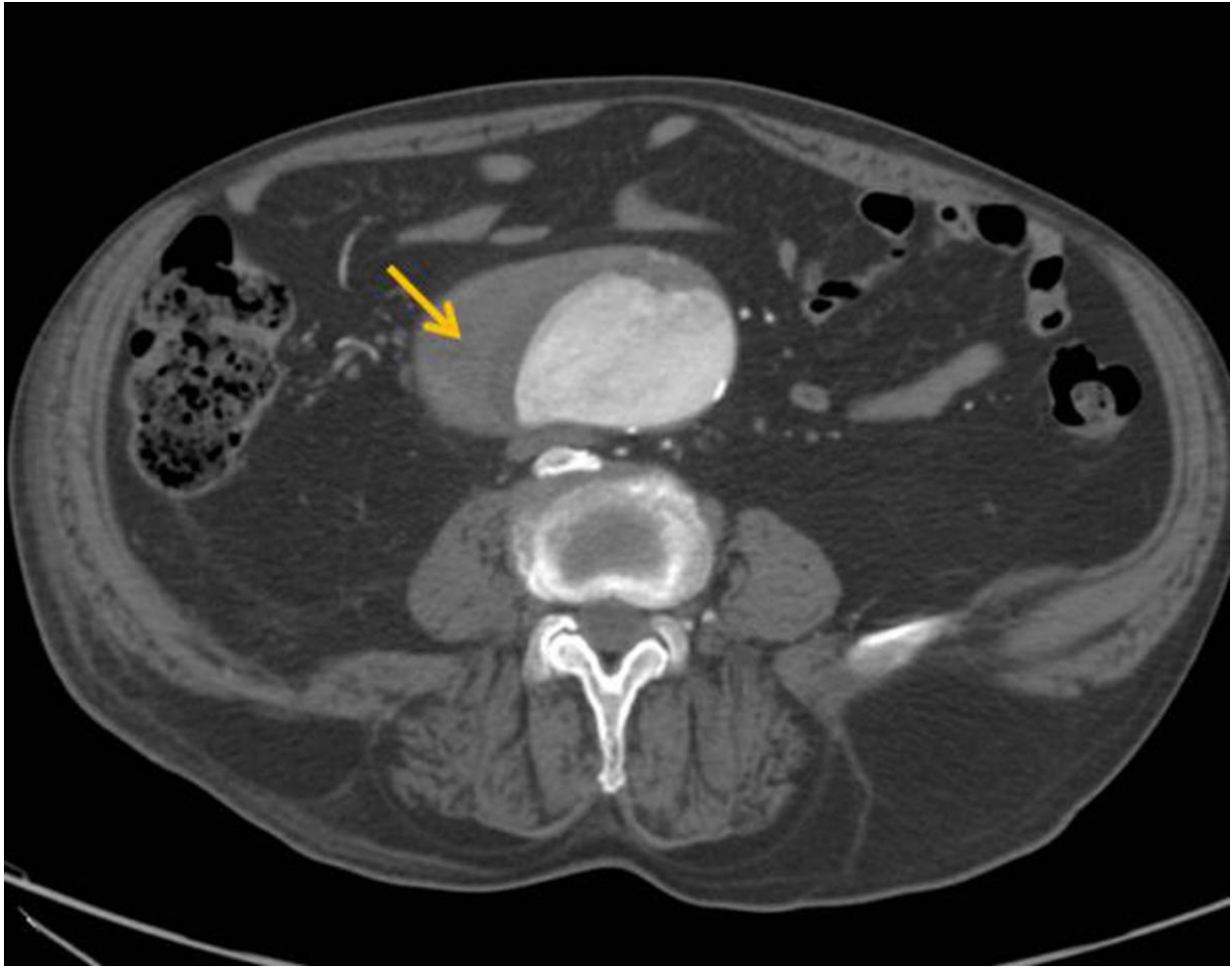
**Fig. 16:** a) b) Non enhanced axial CT images of a patient presenting with a IMH at the ascending aorta (arrow), and descending aorta, with dislocation of the intimal calcification (arrow heads); c) at enhanced axial CT images there is opacification of the area associated with the intramural hematoma (\*), due to a atherosclerotic penetrating ulcer located below.



**Fig. 17:** Non enhanced axial CT images a) d), enhanced axial CT images b) c) e) and 3 d volume rendering images f) g) of a patient with multiple penetrating atherosclerotic ulcers (arrow). It is possible to depict the presence of a intramural hematoma (arrow heads) that clearly identifies the ulcer as penetrating. In the aortic bifurcation there are pseudoaneurysms (\*) due to the progression of PAU

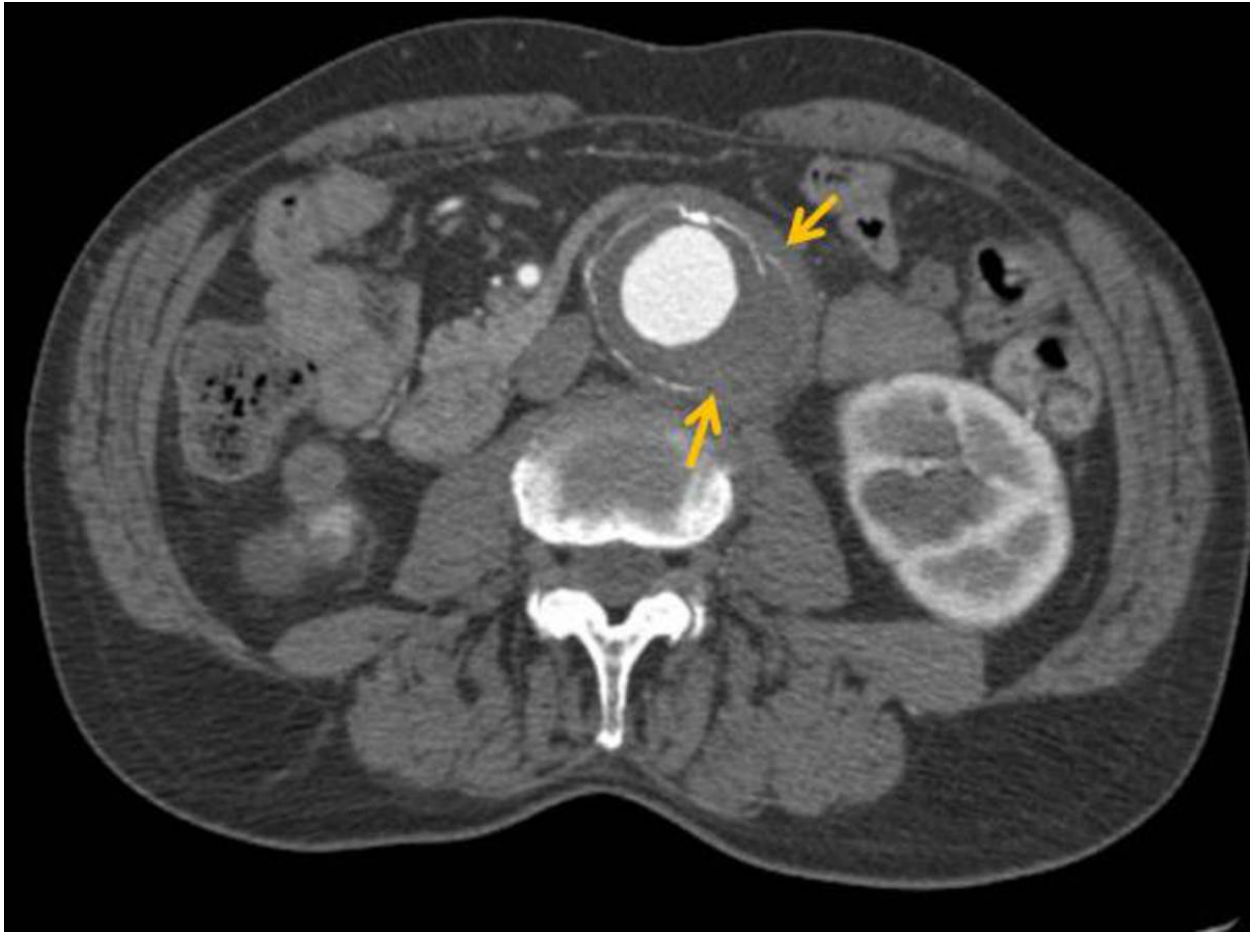

**Fig. 18:** Enhanced axial CT image of a patient with 2 small penetrating atherosclerotic ulcers in the aortic arch (arrows)

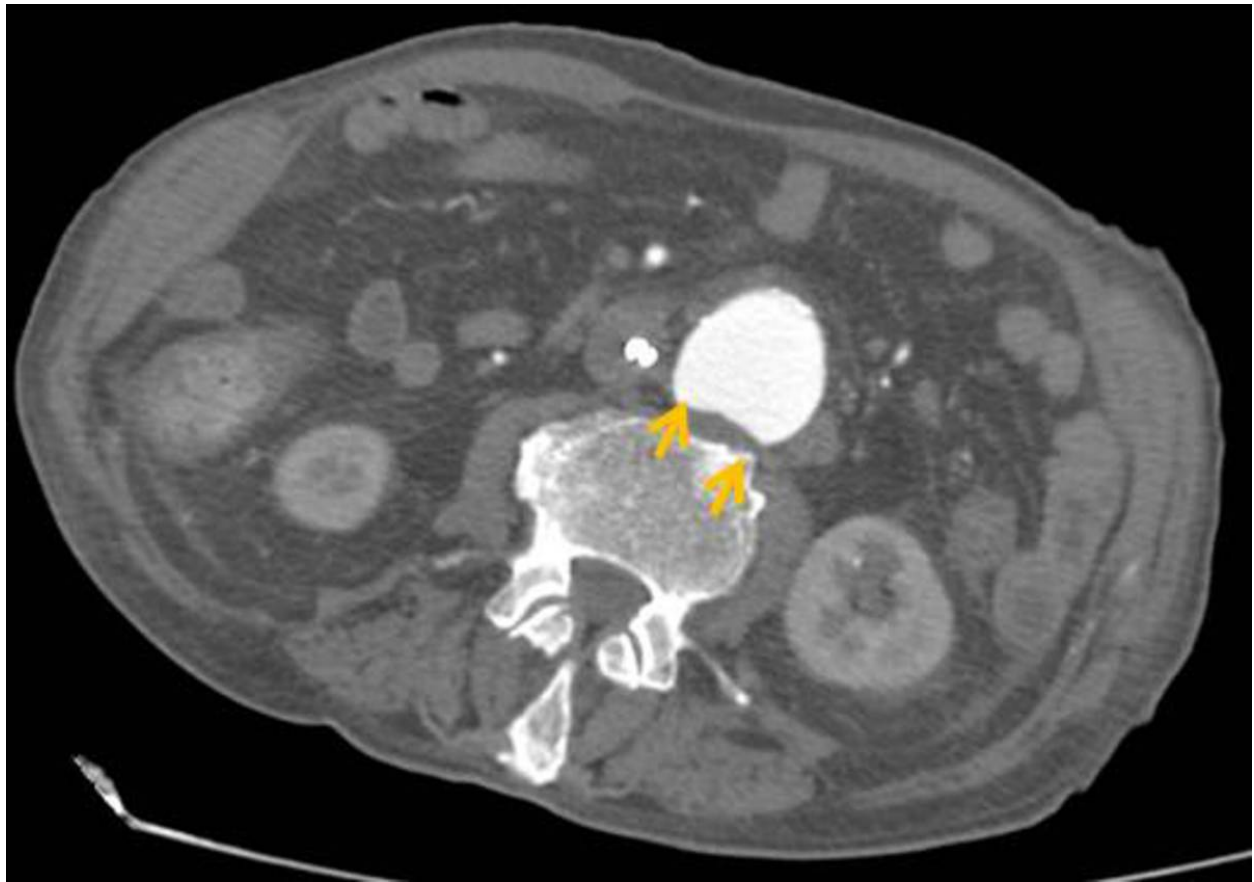


**Fig. 20:** Enhanced axial CT image of a patient with an infra-renal fusiform abdominal aortic aneurysm showing the crescent sign (arrow)

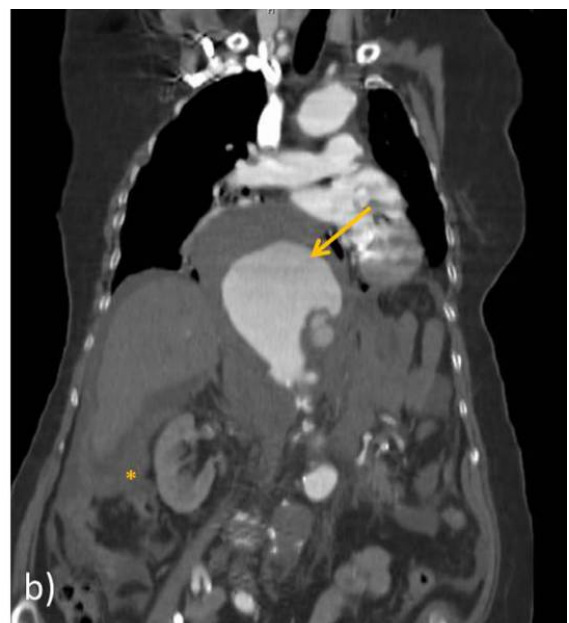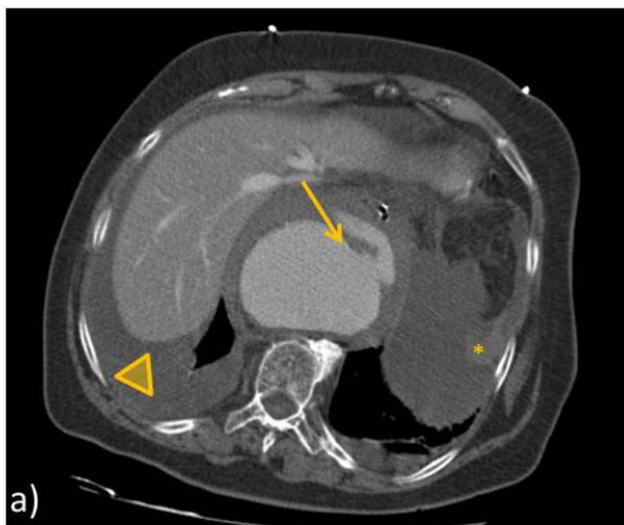




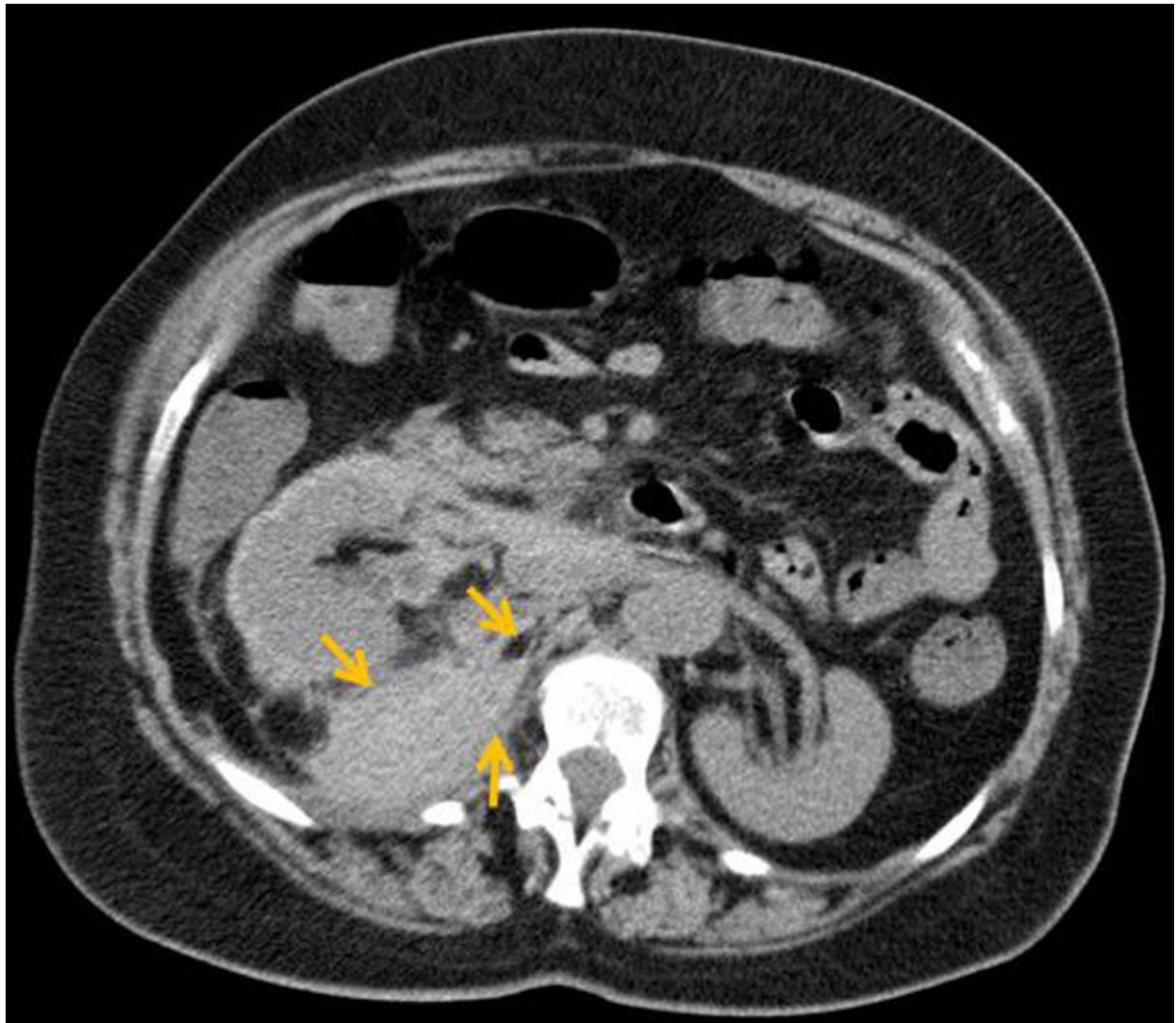
**Fig. 21:** Enhanced axial CT image of a patient with focal discontinuity of the intimal calcifications as a sign of impending rupture (arrows)



**Fig. 22:** Enhanced axial CT image of a patient with an unidentifiable posterior aortic wall (arrows), representing the drapped aorta sign.

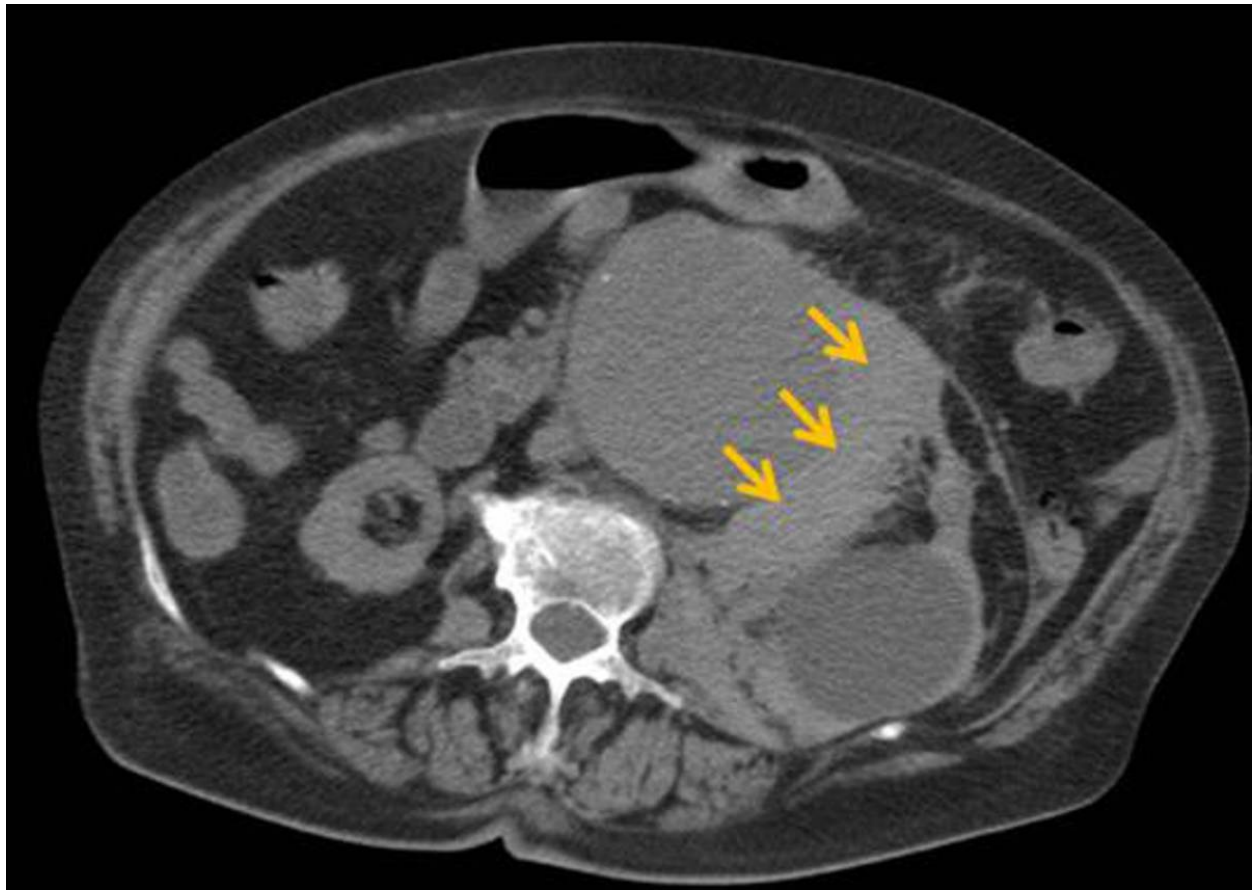


**Fig. 23:** Enhanced axial CT image a) and coronal reformation b) of a patient with rupture of an supra-renal abdominal aortic aneurysm (arrows), and presenting with pleural effusion (arrow head) and hemoperitoneum (\*)



**Fig. 24:** Non enhanced axial CT image of a patient with abdominal aorta rupture showing increased attenuation or stranding of the retroperitoneal fat adjacent to the aorta, inferior vena cava, right kidney, obscuring its margins (arrow)





**Fig. 25:** Non enhanced axial CT image of a patient presenting with acute hemorrhage due to rupture of a abdominal aortic aneurysm, being the hemorrhage isodense to the muscles

## Conclusion

With precise understanding of the current concepts and features of subtypes of acute aortic syndrome, multidetector computed tomography is of paramount importance in the accurate diagnosis. The radiologist should be familiarized with the key concepts behind the imaging findings in acute aortic syndromes, assuming an active role not only in diagnosis, but also in patient management and outcome.

## Personal Information

Hugo Tiago Nunes Correia

Estrada Nacional 337, Figueiró

3510-733 São Cipriano, Viseu

hgnunescorreia@gmail.com

## References

- [1] Vilacosta I, San Roman JA, et al. Acute aortic syndrome, Heart, 2001; 85:365-8
- [2] Yoo SM, Lee HY, White CS, MDCT evaluation of acute aortic syndrome, Radiol Clin N Am, 2010; 48:67-83
- [3] Manghat NE, Morgan-Hughes GJ, Roobottom CA. Multi-detector row computed tomography: Imaging in acute aortic syndrome. Clinical radiology, 2005; 60:1256-1267
- [4] Gonçalves FB, Freiburg CB, Metz R, et al. Acute aortic syndromes. Endovascular today, 2010, Nov, 43-48
- [5] Svensson LG, Labib SB, Eisenhauer AC, et al. Intimal tear without hematoma: an important variant of aortic dissection that can elude current imaging techniques. Circulation. 1999; 99:1331-1336
- [6] Krukenberg E. Beiträge zur frage des aneurysma dissecan. Beitr Pathol Anat Allg Pathol. 1920; 67:329-351
- [7] Lansman SL, Saunders PC, Malekan R et al. Acute aortic syndrome. J Thorac Cardiovasc Surg 2010; 140:S92-S97
- [8] Shennan T. Dissecting aneurysms. Medical research council, Special report series, No 193. 1934

- [9] Botta L, Buttazzi K, Russo V, et al. Endovascular repair for penetrating atherosclerotic ulcers of the descending thoracic aorta: early and mid-term results. *Ann Thorac Surg.* 2008; 85:987-992
- [10] Lee J, Radiological imaging of aortic aneurysms. *Korean Circulation J.* 2007; 37:337-347
- [11] Sebastia C, Pallisa E, Quiroga S, et al. Aortic Dissection: Diagnosis and Follow-up with Helical CT. *Radiographics* 1999; 19:45-60
- [12] Siegel CL, Cohan RH. CT of abdominal aortic aneurysm. *Am J Roentegenol.* 1994; 163:17-29